

INTO *the* HEARTLAND CAMPAIGN

SITE: ROSTOV-ON-DON
DISTRICT: SOUTHERN
COLLABORATION LAUNCHED: 2009

SEPT 26-OCT 6, 2012
SURGICAL-EDUCATIONAL
MISSION 4



Natalia K. (right): Natalia had been searching her entire life for the open heart surgery to repair her heart defect, Tetralogy of Fallot. When she woke up from her successful surgery on October 3, Natalia told us, “My birthday is October 26, but I will forever consider today a second birthday. I am so grateful.”

TETRALOGY OF FALLOT: ‘TET BABIES’ ROMAN, KIRILL, AND MAXIM

Worldwide, Tetralogy of Fallot (TOF) is the most common cyanotic, or “blue baby,” congenital heart defect. Each TOF case requires an individualized course of treatment and a carefully considered surgical approach. In the United States, where heart defects are readily diagnosed at birth, a baby born with TOF will most likely undergo open heart surgery within the first year of life. Because TOF ranges widely in complexity and severity, it is a difficult lesion for emerging Russian teams to master.

Among the five open heart surgeries the joint Heart to Heart-Rostov team performed on this mission, three were complete TOF repairs, each of which presented excellent teaching opportunities for different reasons.

Roman, now 22, was diagnosed with TOF in childhood. Unfortunately, no surgery was available for him in Russia at the time. Four years ago – still unable to receive a complete

correction of his defect – Roman underwent a palliative procedure. Read inside about how we were able to give this medical student the complete repair his mother had pursued for him for over two decades.

Unlike Roman, 10-year-old Kirill had not yet undergone open heart surgery to address his TOF. Kirill’s condition, despite his robust appearance, had become severe. Thorough discussion of his complex case, enabled local specialists to better understand the negative physiological effects of delaying complete repair. Kirill was discharged in time to celebrate his eleventh birthday at home.

Baby Maxim underwent open heart surgery in his ideal window of opportunity – at 10 months. This toddler can look forward to a normal, active childhood: he will be able to enter elementary school on time, and the only reminder of his surgery will be the scar on his chest.



PATIENT PROFILE

Name	Roman T.
Age	22 years old
DOB	August 25, 1990
Weight	Current: 110 lbs
Home	Taganrog, Rostov Oblast 40 mi from Rostov-on-Don
Parents	Maria, 56 (single mother)
Diagnosis	Tetralogy of Fallot S/p Left BT shunt (2008, Rostov-on-Don)
Open heart surgery	Tetralogy of Fallot complete repair October 2, 2012
Discharged from ICU	October 4, 2012
Discharged from hospital	October 17, 2012

Based on an interview conducted in Rostov-on-Don in Russian, by Albina Popov, Heart to Heart staff.

ROMAN: FAMILY BACKGROUND

Roman lives with his mother Maria in a nearby town called Taganrog. Maria tells us that, after giving birth to Roman, she felt she was too old to have another child, so he has no siblings. Maria, now retired, enjoyed a career as a teacher. Currently, Roman is enrolled in medical school, from which he has taken a leave of absence in order to have his heart repaired. He anticipates resuming his studies in 2013.

DEVELOPMENT AND MEDICAL HISTORY

Roman was diagnosed with an unspecified congenital heart defect at birth, but received no cardiac intervention during his early childhood. Before being allowed to enter elementary school at the customary age of seven, Roman underwent a complete physical examination, which confirmed a diagnosis of Tetralogy of Fallot (TOF). Roman was then referred to a pediatric cardiologist in Rostov-on-Don. Subsequently, he has undergone annual examinations at the Rostov-on-Don Regional Cardiac Center. Each year, specialists reconfirmed Roman's need for TOF surgery. His mother continued her desperate search for a surgeon capable of performing a complete TOF repair. Sadly, in the 1990s and 2000s, this surgery was not available to the vast majority of Russian children in need of this operation.

In 2008, Roman underwent a palliative operation to relieve his symptoms – a Blalock-Taussig (BT) Shunt to buy him time until a complete repair of his heart could be attempted. The BT Shunt is the first surgical procedure ever offered to oxygen-starved “blue babies” (1945). It is named after two eminent physicians, Doctors Alfred Blalock and Helen Taussig, for their seminal contributions to pediatric cardiology and cardiac surgery.

Since Roman's procedure in 2008, the local team at the Rostov-on-Don Regional Cardiac Center has continued to monitor him closely.

CURRENT CONDITION AND PROGNOSIS

At the pre-surgical consultation with Roman and his mother, Heart to Heart medical volunteer Dr. Evgeny Krivoshchekov explained the risk factors associated with a complete repair. Adult patients often have a harder time recovering from TOF surgery than younger children. Roman's heart has been working under stress for 22 years, causing the muscle tissue of his left ventricle to thicken and contraction to slow. Although the surgery relieves the stress on the left ventricle, the muscle tissue will need some time to “relax into” a normal workload. During the adjustment period it is common for adult patients to experience arrhythmias and even cardiac arrest.

To prepare for the potential complication of an arrhythmia, the Heart to Heart ICU team ensured that a defibrillator would be at Roman's bedside. Fortunately, Roman's recovery was uneventful. On our visit to him the day after his surgery, he was sitting up in his ICU bed quietly reading a magazine. Two days after his surgery, he was discharged from the ICU.

Roman will need regular cardiac follow up, but is not expected to require additional surgery in the foreseeable future. Without surgery, Roman would have been lucky to live to the age of 30. Now he can look forward to a full, active life with a normal life expectancy. We wish him all the best in his future as a doctor!



PATIENT PROFILE

Name	Kirill T.
Age	10 years old
DOB	November 11, 2001
Weight	At birth: 7 lbs 13 oz Current: 79 lbs
Home	Taganrog, Rostov Oblast 40 mi from Rostov-on-Don
Parents	Irina, 34; Vasiliy, 38
Diagnosis	Tetralogy of Fallot
Open heart surgery	Tetralogy of Fallot complete repair with VSD fenestration October 5, 2012
Discharged from ICU	October 10, 2012
Discharged from hospital	October 24, 2012

Based on an interview conducted in Rostov-on-Don in Russian, by Albina Popov, Heart to Heart staff.

KIRILL: FAMILY BACKGROUND

Kirill lives in Taganrog with his parents, Irina and Vasiliy, and his 9-year-old brother. Both children attend school (often children with heart defects are not allowed to enroll in public schools). Irina works as an accountant.

DEVELOPMENT AND MEDICAL HISTORY

Kirill was diagnosed with a congenital heart defect at birth. At six months of age, he was diagnosed with Tetralogy of Fallot (TOF) at the Rostov-on-Don Regional Cardiac Center. Unfortunately, at the time, the surgical team was hesitant about undertaking a complete TOF repair on Kirill. Irina made efforts to have Kirill undergo surgery at the Bakulev Center in Moscow, but he was not accepted.

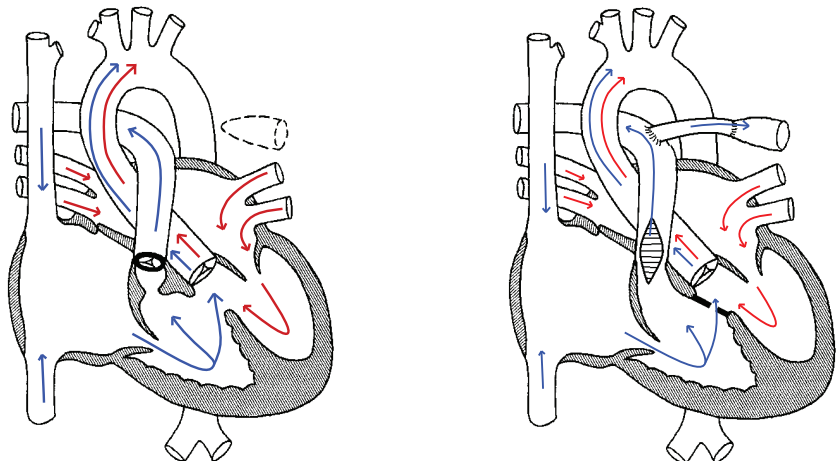
When the Heart to Heart team met ten-year-old Kirill, he still had not undergone any surgical intervention. On October 1, the joint team performed a diagnostic catheterization to measure important parameters within the chambers of his heart. The team ascertained that Kirill's current condition had become severe. Detailed data about cardiac pressures and blood flow rates helped determine the best surgical approach for Kirill's repair.

CURRENT CONDITION AND PROGNOSIS

The joint Heart to Heart-Rostov team performed open heart surgery on Kirill on October 5. Near the culmination of the procedure, the operating room team observed that the blood pressure in the right ventricle of Kirill's heart had become dangerously elevated. In order to relieve the pressure, a small opening was made between the two ventricles. This will allow pressures in the heart to gradually adjust to normal levels. In the future, it may become necessary to close this small opening. Lead surgeon Dr. Krivoshechekov suggested that the closure could be performed via interventional catheterization, sparing Kirill a second open heart procedure.

After two weeks on the pediatric ward, Kirill was discharged from the hospital and returned home with his parents shortly before his eleventh birthday.

KIRILL'S HEART: BEFORE AND AFTER



Before: Kirill's heart is unable to pump enough blood into his lungs to be oxygenated due to the obstruction at and below the pulmonary valve. Instead, the blue blood is diverted through a large hole between the two lower chambers (VSD). **After:** Placement of a tube from the main pulmonary artery to the left pulmonary artery branch increases the amount of blood flowing to both of Kirill's lungs. A patch is used to relieve the obstruction near the pulmonary valve. This aids circulation and improves the pumping efficacy of the right ventricle.



PATIENT PROFILE

Name	Maxim D.
Age	10 months old
DOB	November 30, 2011
Weight	At birth: 8 lbs 6 oz Current: 24 lbs
Home	Rostov-on-Don
Parents	Natalia, 31; Maxim, 40
Diagnosis	Tetralogy of Fallot, DORV
Open heart surgery	Complete TOF repair with VSD closure October 1, 2012
Discharged from ICU	October 2, 2012
Discharged from hospital	October 10, 2012

Based on an interview conducted in Rostov-on-Don in Russian, by Albina Popov, Heart to Heart staff.

MAXIM: FAMILY BACKGROUND

Baby Maxim lives with his parents and his seven-year-old sister Miroslava in Rostov-on-Don. Both parents are medical professionals: Natalia is a pediatric neurologist, and Maxim senior is a psychologist.

DEVELOPMENT AND MEDICAL HISTORY

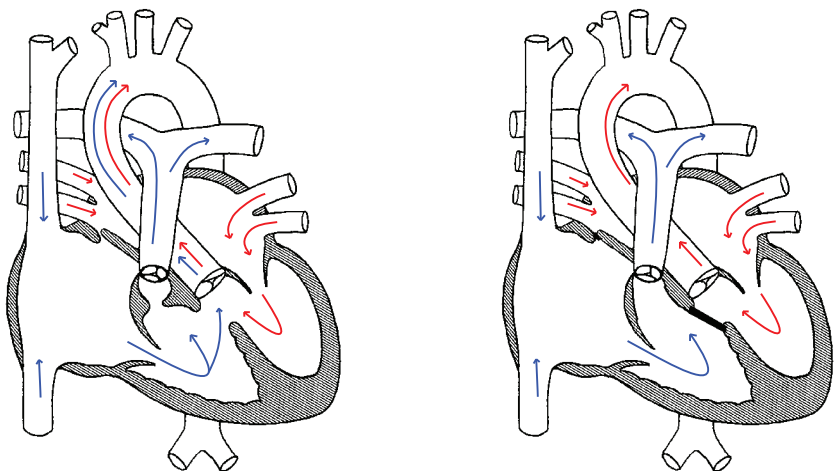
Maxim was born at a local hospital last Fall. One week after his birth, a heart defect was detected. The family was referred to the Rostov-on-Don Regional Cardiac Center, where cardiologist Dr. Daria Petrova was immediately assigned to further diagnose the baby's heart condition. Dr. Petrova diagnosed Maxim with Tetralogy of Fallot (TOF). She recommended that he be closely followed, while allowing him to grow as much as possible before attempting a complete TOF repair. Since the family's first visit to the cardiac center, Natalia has been bringing Baby Maxim back at least once a month for follow-up echo examinations.

Despite his heart condition, Maxim is a relatively healthy toddler: he is not at all cyanotic (blue); he has gained weight easily; and his mental development is on track. When Heart to Heart meets Maxim, our team quickly assesses that he is now an ideal candidate for a complete surgical repair. Additionally, his case provides an ideal teaching opportunity for a discussion about the timing of TOF repair. He was scheduled as the joint team's first surgical case of the mission.

CURRENT CONDITION AND PROGNOSIS

Maxim underwent open heart surgery on October 1. The operation was led by Heart to Heart medical volunteer Dr. Evgeny Krivoshchekov, one of Russia's most accomplished pediatric cardiac surgeons. The surgery went well and Baby Maxim's recovery in the pediatric cardiac intensive care unit (PCICU) was brief and uneventful. He was discharged from the PCICU the following day. Natalia anticipated staying with Maxim at the hospital for another two weeks – the norm at Russian cardiac centers. Dr. Petrova will continue to follow Maxim, and Heart to Heart looks forward to conducting our own follow-up exams on Maxim in the future.

MAXIM'S HEART: BEFORE AND AFTER



Before: The hole between the left and right ventricles (VSD) allows non-oxygenated (blue) blood to mix with oxygenated (red) blood and circulate to Maxim's body. **After:** Closing the hole reduces the amount of blue blood flowing to his body. TOF surgery also increases blood flow from the right ventricle to the lungs, in turn increasing the amount of oxygenated blood delivered to Maxim's body.